THE BASICS OF POINT-OF-CARE ULTRASOUND FOR THE GENERAL PEDIATRICIAN

Table of Contents

Information and Images adapted from Doniger, Stephanie J. *Pediatric Emergency and Critical Care Ultrasound*. Cambridge: Cambridge University Press, 2013. Print.

PLEASE FILL OUT THE FOLLOWING SURVEY AT THE BEGINNING AND END OF EACH PEM ROTATION

https://ufl.qualtrics.com/jfe/form/SV_5usSxaJoGJHlN4h

Aims

Point-of-care (POC) ultrasound is an accessible clinical tool, much like the stethoscope when it was first introduced. It can be interpreted by both skilled and training physicians to augment diagnosing capacities, amplify clinical management, and improve procedural skills. Many other fields in medicine have incorporated its use into practice. Pediatrics continues to evolve in its introduction into several subspecialties, such as emergency medicine, intensive care, rheumatology, and cardiology. However, there are a number of underutilized relevant ultrasound applications that can quickly and easily be utilized in any general pediatrics office.

Overall, there are many useful ultrasound modalities and techniques that can be beneficial in the outpatient and inpatient setting. It can be beneficial as it can make care safer with less procedural complications, more efficient bedside diagnosis, and less cost in a diagnostic medical world.

The obvious counter arguments against ultrasound stem from their limitations and challenges. Many applications of POC ultrasound require competency and adequate bedside skill use. However, there are numerous studies that indicate that novice sonographers can learn a variety of individual ultrasound applications with good accuracy. In fact, a study indicated that 95.9% of emergency medicine residents were able to reach an "expert-level" of point-of-care ultrasound competency with 25-50 scans of a particular study. Although skepticism of its use in pediatrics exists, ultrasound is meant to be a bedside technique and requires experience. Basic concepts to point of care ultrasound should not be overlooked by a pediatrician as it is a safe and effective diagnosing tool, particularly in austere medical environments.

The purpose of this introductory curriculum is to allow our pediatric trainees exposure to POC ultrasound early on in their training through in depth overviews of some common exam techniques, which include pulmonary point-of-care, eFAST, skin and musculoskeletal point-of-care, transabdominal point-of-care ultrasound for adolescent females, and evaluation of the inferior vena cava in hydration status. By exposing and immersing our pediatric residents to the ultrasound machine and transducers, we hope to provide an auxiliary method of bedside diagnosis that will continue to make our graduates well rounded pediatricians of the future.

Objectives

Implementation of the ultrasound curriculum expects that residents will be able to:

1. Describe the basics of how ultrasound works and knobology to another learner.
2. Perform and interpret pulmonary POC, eFAST, skin and musculoskeletal POC, transabdominal POC of an adolescent female, and IVC evaluation.
3. Acquire at least 5 scans during each pediatric trainee's first year rotations and 10 scans during their second year rotation. Each scan will be verified by an attending and documented as a *procedure* on New Innovations.
4. Inspire increased usage of POC ultrasound in an outpatient, inpatient, ED, and ICU settings.

Section 1. Introduction and Knobology

Ultrasound Physics and Knobology (54m 00s) https://vimeo.com/46937198	Ultrasound Physics and Machinery (20m 49s) https://vimeo.com/94786374
Transducers 14m 00s Knobology 26m 54s M-mode 36m 00s Doppler 37m 26s Artifacts 44m 30s	Physics 00m 14s Echogenicity 1m 04s Transducer 2m 23s Planes 3m 48s M-Mode 06m 17s Doppler 08m 00s Knobology 08m 29s Artifacts 10m 57s

The pulse-echo principle in point-of-care (POC) ultrasound is based on the propagation of longitudinal sound waves into the human body and "listens" for returning echoes. Transducers contain piezoelectric ceramic crystals that convert electrical energy into sound waves at 1540 m/s, the average speed of sound in humans at body temperature.

ATTENUATION is the *loss of energy* or *weakening* of sound waves. Energy is absorbed by surrounding tissues, released as heat, reflected, refracted, or scattered.

- **Reflection** is the redirection of sound waves back to its source.
- **Refraction** is the redirection of part of the sound wave as two mediums are crossed with different propagation speeds.
- **Scattering** occurs when sound waves encounter irregular surfaces or a surface smaller than the sound beam.

ACOUSTIC IMPEDANCE refers to the *tissue's resistance to molecular movement*, which is directly related to density. **Acoustic mismatch** is the largest acoustic impedance leading to lesser energy in deeper structures. **Acoustic windows** are sounds that go through tissues of similar acoustic impedance allowing for deeper penetration.

MODES OF SCANNING

- **A-Mode**
- **B-Mode ("B" for brightness)** is the primary imaging modality in POC ultrasound with 256 shades of gray. Echogenicity stems from intensity or brightness of this imaging.
  - **Hyperechoic**: structures produce brighter ("whiter") echoes
  - **Hypoechoic**: structures give weaker echoes than surrounding tissues
  - **Isoechoic**: tissues are of similar echogenicity and will be uniform
  - **Anechoic**: structures do not produce ("black") echoes

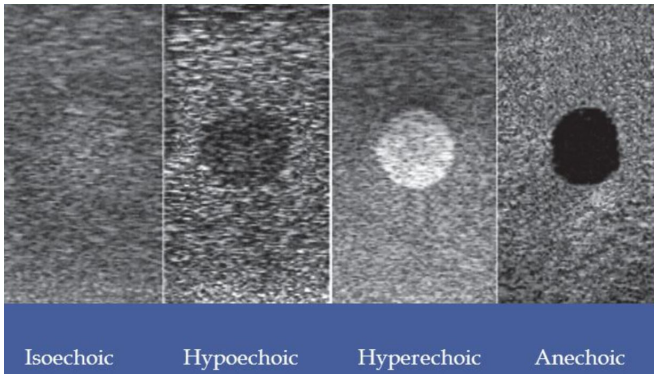

- **M-Mode ("M" for motion)** records motion changes along the path of the B-mode image. An x-y plot is created where the y-axis is the distance from the transducer, and the x-axis represents time.
- **Doppler** is the change in frequency of the acoustic wave. It analyzes velocity and direction of motion, most notably blood flow. There are several types of Doppler.
  - Audible Doppler
  - Spectral (pulse wave) Doppler
  - Color Doppler shows intensity and direction of movement of higher flow states

        - Know the mnemonic “BART” for “blue away and red toward,” which depicts direction of high flow to the transducer.
    - Power Doppler is similar to Color Doppler although it is more sensitive in detecting frequency shifts in low flow states (ie. testes)

TRANSDUCERS (“PROBES”)

- Ultrasound transducers are produced in different shapes and sizes by several manufacturers. The choice of the transducer must reflect the clinical indication and anatomy.
- Each transducer has a marker (“indicator”, blue dot), which allows the ultrasonographer to orient with the screen.
- The screen marker should be oriented to the **top-left** for ease.
- **GEL is your friend!** In order to transmit ultrasound waves, gel or another medium needs to be placed on the transducer footprint. There are non-sterile and sterile forms.



Phased/Sector Array Transducer ● Flat square footprint with clustered crystals, therefore, a pie-shaped image on screen ● 1.5 to 4 MHz ● Used in the majority of pediatric cases and useful in cardiac and pulmonary POC
Linear Array Transducer ● Flat rectangular footprint with linearly aligned crystals, therefore, a rectangular image on screen ● 5 to 12 MHz (*highest frequency*) ● Maximum depth of approximately 6 centimeters ● Useful in vascular POC and ultrasound guided procedures
Curvilinear/Convex Array Transducer ● Curved footprint with crystals in juxtaposition, therefore, a sector-shaped image on screen   ○ “Microconvex,” typically available in the NICU, are smaller versions that may be more readily used in the pediatric population. ● 2 to 5 MHz ● Useful in abdominal POC. This is rarely used in the pediatric population, unless patients are adult-size

TRANSDUCER TECHNIQUES

- **Fanning** (“sweeping”) is the act of moving the transducer along an imaginary arc without removing footprint from skin
- **Rocking** is the act of tilting with one edge of the transducer off of the skin
- **Rotating** is the act of twisting clockwise or counterclockwise

Knobology

Knobology, referred to as knowledge of “knobs” is the basic understanding of the ultrasound machine’s buttons. Different manufacturers may produce different machines.

Know these four buttons on any ultrasound machine. Power. Gain. Depth. Freeze.

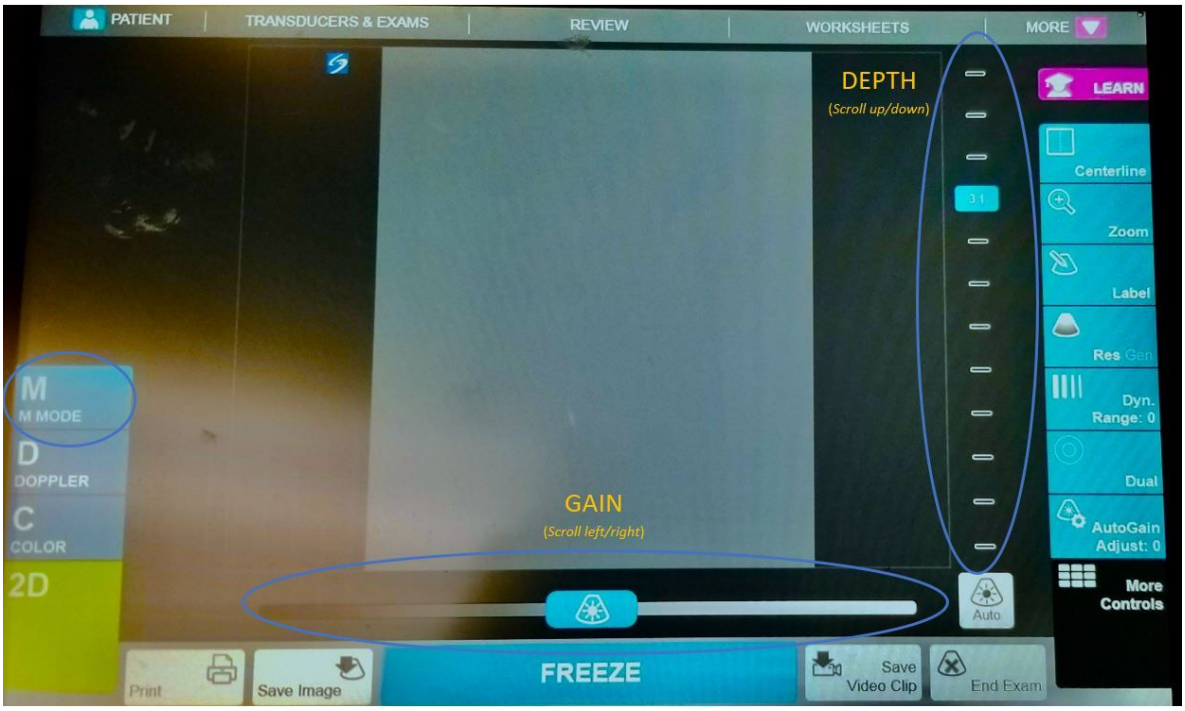

Resolution is defined as the ability to discriminate two separate objects, otherwise, overall image quality

- Spatial Resolution is
  - Axial resolution: discriminating objects in the scanning plane
  - Lateral resolution: discriminating objects perpendicular to the scanning plane
- The inter-relationship between frequency, axial resolution, and depth is fundamental.
- **Resolution and Depth (Penetration) is dependent on Frequency.**
  - **High frequency >> High Attenuation >> Shallow Depth >> Low Penetration**
  - **Low frequency >> Low Attenuation >> Deeper Depth >> High Penetration**

Gain refers to the to "brightness" of the image, like on a computer monitor. As sound travels, it is attenuated through the tissue and the beam weakens. Ultrasound machines are built to counteract attenuation by making deeper images brighter. Gain allows the ultrasonographer to artificially amplify returning signals to the problem.

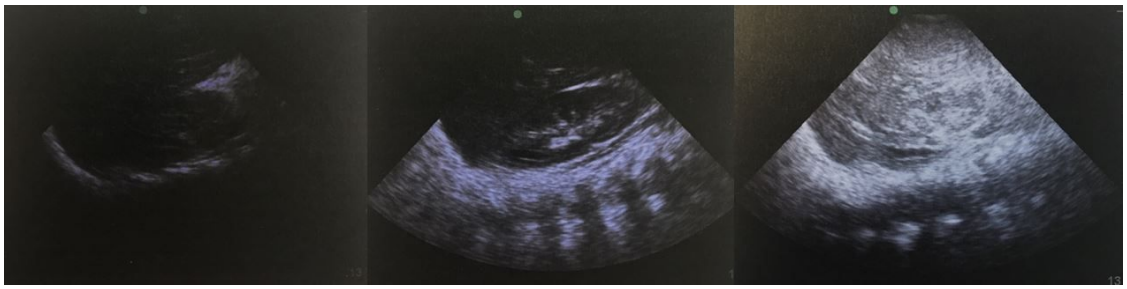

Depth modifies distance between shallow and deeper structures.

- Increasing depth lengthens ultrasound wave time, which decreases the frame rate.
- **Always begin scanning at the deepest depth. Once your structure of interest is identified, decrease depth. Tic marks alongside the screen are equivalent to 10 mm or 1 cm.**
- Maximizing display of structure on the screen optimizes the depth setting.

Zoom enlarges a select area of the image with the same pixels but decreased resolution.

Freeze holds the image on the screen. The ultrasonographer can scroll through the frames leading up to the still image as a result. The cine loop, number of still images frozen at a given time, is determined by the manufacturer.

Artifacts

Artifacts are visual effects that skew physical structures, but their presence may be normal or abnormal depending on the process.

ACOUSTIC SHADOWING ("ATTENUATION ARTIFACT") occurs when sound meets a highly reflective surface that absorb sound energy, leaving behind much less energy to penetrate deeper structures. Highly reflective structures, such as bone and calcifications, allow 30% attenuation, meaning that only 70% of sound energy returns to the transducer.

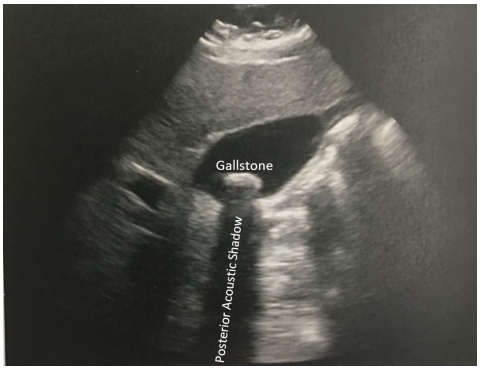

Black ("clean") shadows occur with bone and calcifications as they are highly reflective. This compares to "**dirty" shadows**, which occur through air and soft tissue due to acoustic impedance mismatch.

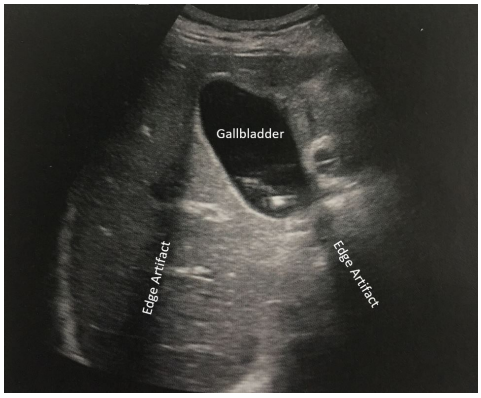

Edge artifact, otherwise known as **lateral cystic shadowing**, arises when sound waves reach curved surfaces, such as a cyst where part of the energy beam is refracted and scattered leading to a thin shadow on each of the lateral sides of the structure.

POSTERIOR ACOUSTIC ENHANCEMENT occurs as the ultrasound wave goes through areas of low energy (attenuation), such as abscesses. This allows for more "energy" to reach deeper structures. However, since the ultrasound beam will weaken (attenuate) as it propagates through the structure, the ultrasound machine does not recognize this and "autocorrects" to amplify the echoes of the deeper structures. The amplification of deeper echoes will be overcompensated and be "artificially brighter" as a result.

- Keep in mind that posterior acoustic enhancement can be corrected by adjusting 'Gain.'

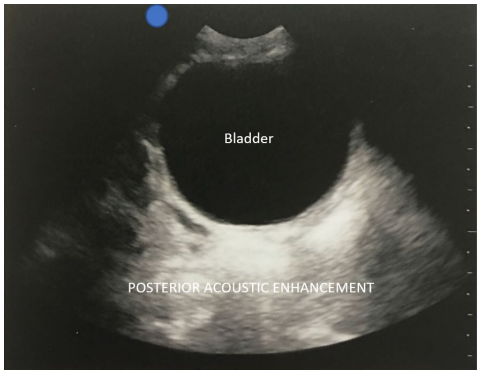

REVERBERATION ARTIFACTS occur from soundwaves bouncing back and forth between two reflective surfaces. They present as repeating bright arcs that are equidistant, which can often be seen in the lung.

1) **A-lines** are repetitive equidistant horizontal flat lines seen on Lung POC Ultrasound. A-lines result from sounds reverberating between the lung pleura and the transducer distal to the brighter pleural line.
2) **Ring-down ("comet tail") artifacts** occur at interfaces between tissue and air or tissue and foreign body. This appears deep to highly reflective surfaces. **B-lines** are a type of ring-down artifact. In fact, multiple B-lines are known as **lung rockets**.

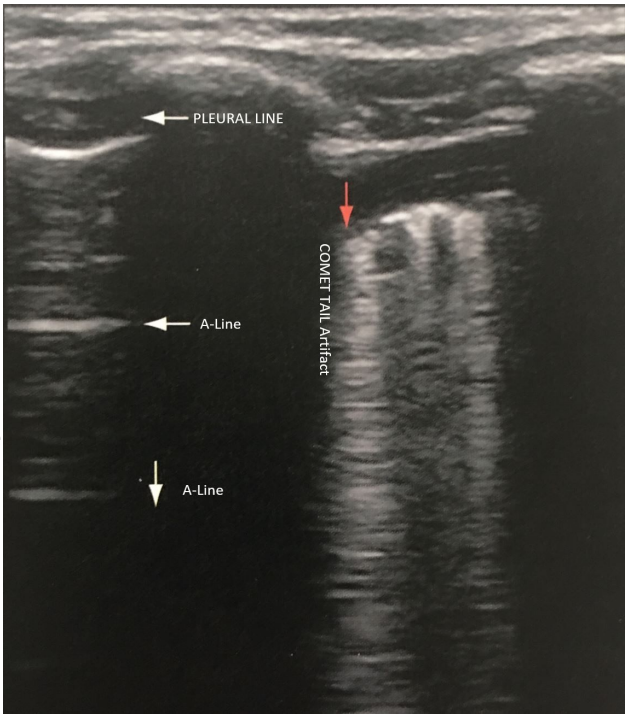

MIRROR IMAGE ARTIFACTS occurs when the sound wave reaches strong reflective surfaces.

THORACIC ULTRASOUND https://vimeo.com/46515236 @ 8m40s

- The soundbeam reaches a highly reflective surface (ie. diaphragm), but instead of directly being received by the transducer, it encounters another structure, such as a nodule, and some of the beams return to the transducer while others reflect back to the highly reflective surface before returning to the transducer.Due to the time lapse, the mirror image is found in the far field of the image.
- The ultrasound machine makes a faulty assumption that the returning echo has only reflected once, but this is not the case. The returning mirror image appears to have returned from the deeper structure, but instead is a simply a secondary reflection.

Section 2. Pulmonary Point of Care Ultrasound

Thoracic Ultrasound (18:56) https://vimeo.com/46515236	**Chest Ultrasound CASES (50:03)** https://vimeo.com/51212231
Technique 03m 26s Mirror Artifact 08m 40s Pleural Effusion 10m 42s Pulmonary Edema 14m 23s Interstitial Disease 14m 42s Pneumonia 15m 15s Limitations 16m 44s	How to Scan 06m 55s B-lines 09m 37s Bat Sign 10m 55s Lung Sliding 12m 35s A-lines 13m 48s B-lines 15m 50s Pneumothorax 20m 21s Trauma Pneumo Algorithm 27m 35s Effusions and Hemothorax 29m 27s Fractures of Chest Wall 33m 16s Consolidations 36m 14s Pulmonary Contusion 38m 01s Cases 38m 20s
Pereda MA, Chavez MA, Hooper-Miele CC et al. **Lung Ultrasound for the Diagnosis of Pneumonia in Children: A Meta-analysis**. doi: 10.1542/peds.2014-2833	

Pulmonary POC can easily be implemented outpatient, in the emergency department, and on the inpatient floor. Pulmonary ultrasound has the benefits of immediate bedside diagnosis of several conditions that have traditionally depended on radiological techniques. **Pulmonary ultrasound success is rooted in the evaluation of artifacts to guide diagnosis, rather than anatomical landmarks**. A smaller footprint transducer is beneficial to allow for imaging between the ribs; however, it should not be small enough so that ribs cannot be visualized. Remember, artifact is integral for pulmonary point-of-care ultrasound and ribs are necessary as a reference point in comparison to the pleural line and lung sliding. A child's thinner chest wall and smaller thoracic width allows for optimal pulmonary ultrasound.

NORMAL LUNG

- Pleural line: hyperechoic line deep to ribs
- Ribs: visual reference and assist with evaluation of artifacts. Posterior shadows are normal as they follow the transducer array (Linear Transducer: parallel rib shadows and image pane will be square/rectangular vs. Phased-array transducer rib shadows are divergent and appear pie-shaped)

Scanning approach

- Longitudinal orientation (vertical) with indicator towards the patient's head
- Horizontal orientation (flat) with indicator pointed laterally in the same direction as image pane can be used for increasing the surface of the visualized pleura and very useful for *lung sliding*.

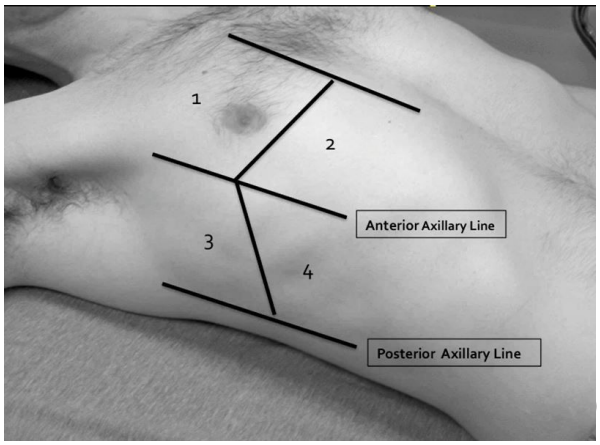

Artifacts

"Bat sign": two rib shadows with pleural line in between seen with longitudinal orientation

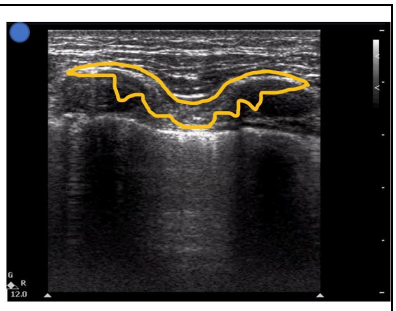

Lung Sliding
Visceral pleura gliding on the parietal pleura creates a straight hyperechoic line which is synchronized with breathing

- There is slight rough textured appearance to it which is due to reflexion of the ultrasound on the alveolar surface within the parenchyma
- Prominent lung sliding occurs at the bases where there is maximal pulmonary expansion and pleural gliding
- **"Curtain sign"** is a normal finding where aerated lung slides in the image pane covering subdiaphragmatic structures
- Do not confuse on left chest as cardiac movement can be confused with "lung sliding"

A-lines ("A" for "air")

- Reverberation artifact between pleura and transducer causing horizontal lines parallel to the pleural line that is best seen when perpendicularly scanned
- Generated by the presence of air (normal or pathologic)

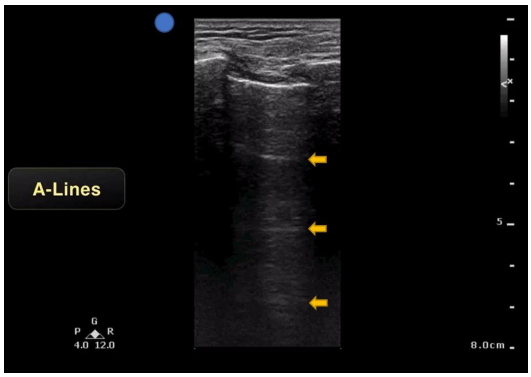

B-lines

This is a type of reverberation artifact, most specifically a *ring down artifact*

Pathologic thickening of the alveolar septa and/or fluid filling the alveoli which is surrounded by air causes hyperintense reverberation artifact and appear as "laser like" hyperechoic parallel lines

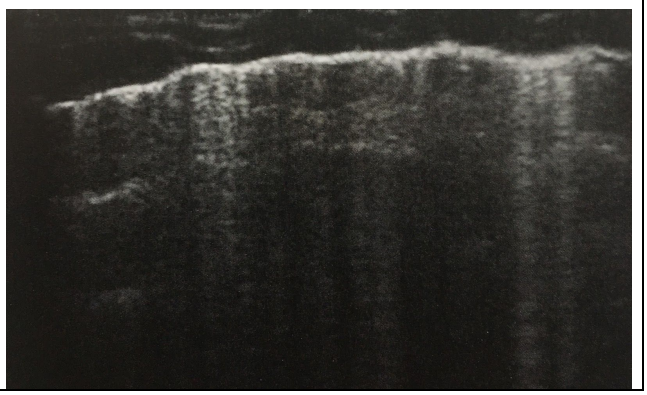

B-lines present with any disease that causes extravascular lung fluid +/- interstitial thickening +/- alveolar fluid accumulation.

B-lines are highly sensitive for:

- acute respiratory distress syndrome (ARDS)
- infantile respiratory distress syndrome (RDS)
- transient tachypnea of the newborn (RRN)
- cardiopulmonary edema
- interstitial pneumonia
- pulmonary contusion

B-lines must do the following

1) multiple hyperechoic well defined vertical lines that start at pleural line
2) move with lung sliding (respiration)
3) extend off of the screen
4) erase A-lines

However, few isolated B-lines may be seen in normal lung bases therefore, **greater than 3 B-lines on a scan is always pathologic and referred to as *lung rockets***, as normal lung will rarely have more than 8 B-lines in the entire pulmonary surface.

C-lines

- "C" for "consolidation"
- C-lines are not artifact but rather the contact between soft tissue and visceral pleura
- Hypoechoic to intermediate echogenicity
- For instance, ARDS may show multiple small subpleural consolidations that are seen in more affected regions
- Air bronchograms can be seen within consolidations

Pathology	Normal Lung	Pneumonia or Atelectasis	Pleural Effusion	Pneumothorax	Interstitial Edema
"Water"	Normal Amount	Water-filled parenchyma	Water ONLY	No Water	Increased Water in Aerated Lung
Artifact	A-lines Lung Sliding	C-lines	No A-lines No B-lines No C-lines	Pure A-lines	B-lines

M-mode essentially is reflection artifact deep to the pleural line. When dynamic, pleural movement synchronizes with a "sparkling pattern"

- Immobile chest wall are the horizontal lines (ocean)
- Sparkling artifact appears as grainy (sandy beach)

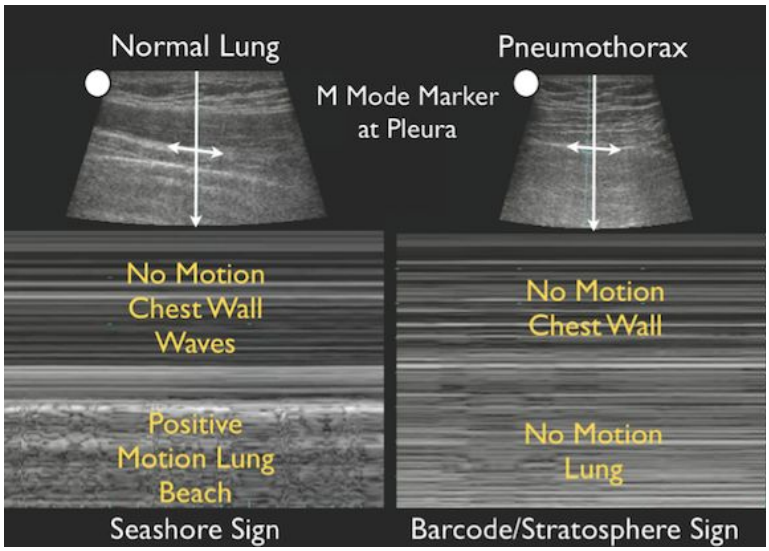

Normal ***seashore sign*** shows *waves* superficially and *beach* deeper. See left side of image above.

Lung pulse: "short and rapid" seashore sign due to adequate pleural contact but no pulmonary expansion. Rhythmic cardio-synchronous visceral pleural movement that appears to be a "short and rapid" version of the seashore sign. When does it occur? Complete atelectasis, Apnea, Right mainstem intubation.

Abnormal ***stratosphere sign*** (pneumothorax) is caused by the lack of scatter attributed by the alveoli. Ultrasound beam immediately reflects back from the free air directly beneath the parietal pleura. Artifact deep to the pleural line will be static. **All you will see are waves!**

PNEUMONIA & ATELECTASIS

Well organized pneumonias are great conductors of ultrasound waves

Pneumonia is seen primarily as an alveolar process that increases secretions in larger airways. There is no initial airway obstruction and airflow allows secretions to move to-and-fro in the bronchi

- *dynamic air bronchogram sign* = pathognomonic

Surrounding B-lines differentiate pneumonia and atelectasis from other causes of consolidation

PNEUMONIA: Early pneumonia: multiple small (less than 1 cm) C-lines with B-lines or confluent B-lines

- *Hepatization of the lung* is seen when dense consolidation occurs above the diaphragm

ATELECTASIS: Atelectasis resorbs air distal to an occluded airway causing *static air bronchograms*. When lung retracts secondary to the absorption of trapped air, it causes volume reduction and brings bronchovascular structures closer and parallel.

Airways with large fluid and no air movement resemble vessels (*fluid bronchograms*) and are typical of post-obstructive pneumonias. However vessels are hypoechoic and show a Doppler sign.

PULMONARY EDEMA

Severe Pulmonary Edema generates sonographic *white lung* as B-lines overtake the entire pulmonary surface.

Absent B-lines excludes cardiogenic pulmonary edema in 100% of cases.

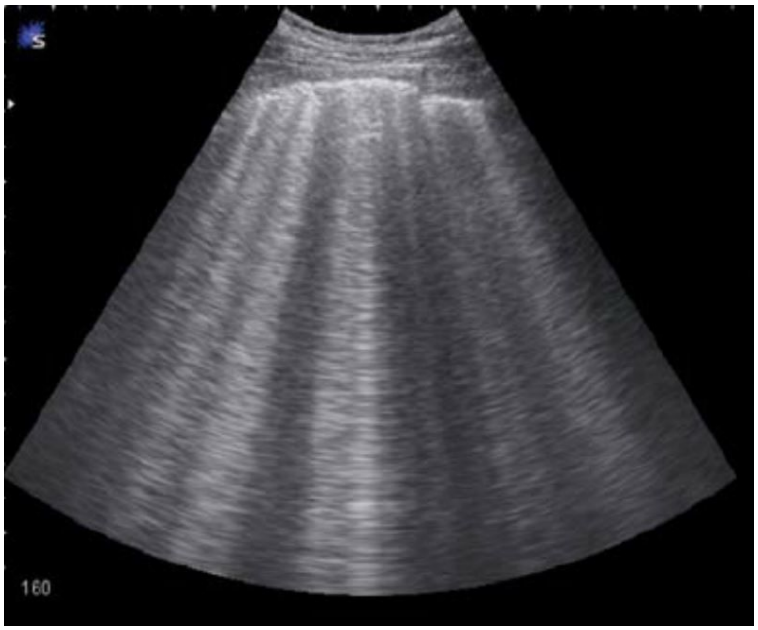

PLEURAL EFFUSION

Atelectatic parenchyma is seen as soft tissue "floating" in the effusion with B-lines representative of an irregular margin of transition to the deeper aerated lungs.

More easily detected in the seated patient.
Visualized as an anechoic layer overlying the parenchyma

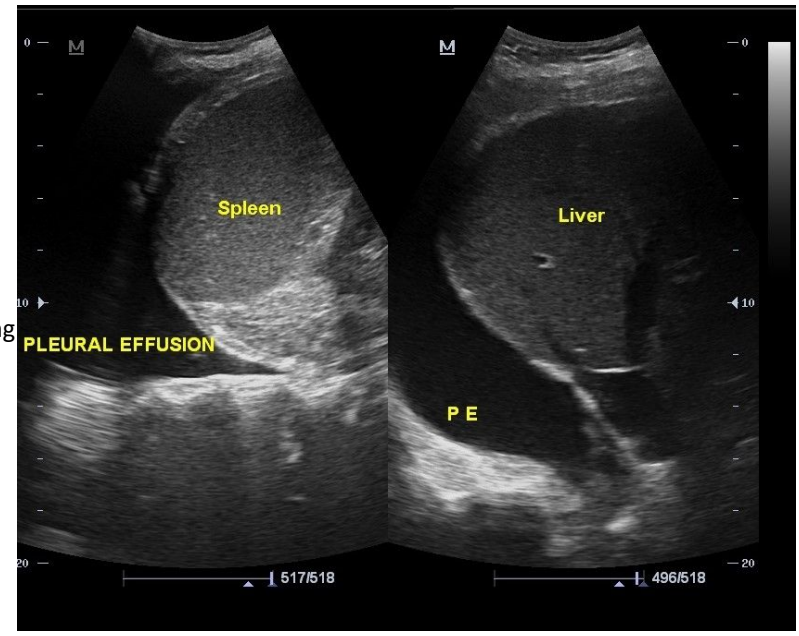

INTERSTITIAL SYNDROMES (TTN and RDS)

Interstitial Syndromes presents with multiple B-lines dues to an increase in extravascular fluid
More easily detected in the seated patient.

All Interstitial Syndromes must have:

1) 3 or more B-lines present <7mm apart from each other
2) 2 or more regions with at least one on each side

Please refer to the following "BLUE Protocol," which summarizes Pulmonary POC findings as a whole.

Lictenstein DA, Meziere GA. Relevance of lung ultrasound in the diagnosis of acute respiratory failure: the BLUE protocol. Chest 2008;134(1):117-25. doi: 10.1378/chest.07-2800.

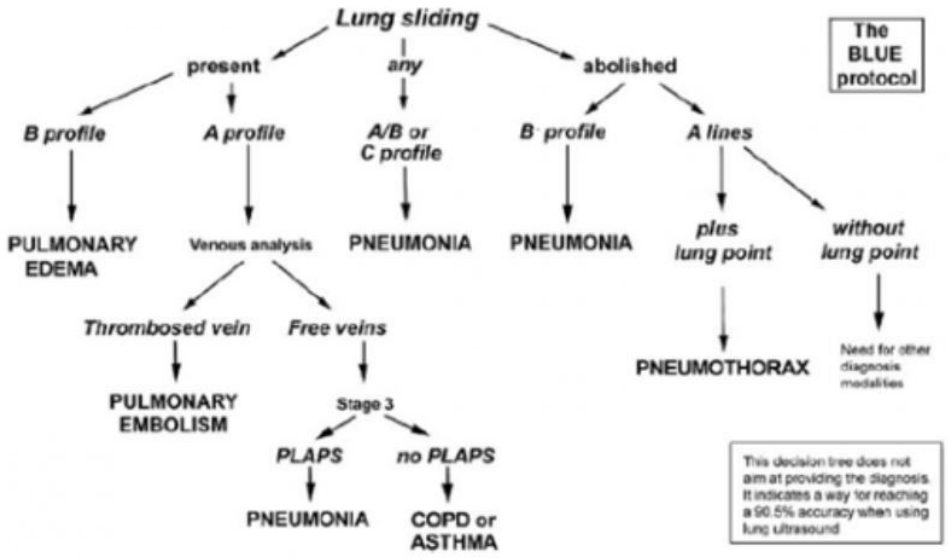

A profile means predominantly A lines
B profile means predominantly multiple anterior diffuse B lines
A / B profile means predominant A lines on one side and predominant B lines on the other side.
C profile means anterior alveolar consolidation(s)
PLAPS means ***posterolateral alveolar and/or pleural syndrome*** detected on a lateral sub-posterior sonological examination.

Section 3. eFAST

FAST Overview (07:25) https://vimeo.com/52896340	e-FAST (20:03) https://vimeo.com/34118863
https://www.acep.org/Content.aspx?id=109321#sm.00038ldmqb0qe9c11lc17wkkcsxg0	

Trauma is the leading cause of pediatric mortality in developed countries, most often related to motor vehicle injuries and blunt abdominal trauma. The majority of blunt abdominal trauma is managed nonoperatively, however, many intra-abdominal injuries undergo CT scans which have significant radiation exposure. The extended focused assessment with sonography for trauma (eFAST) is meant to detect any free fluid in the dependent areas of the thorax and abdomen. **A suboptimal eFAST (ie. body habitus, subcutaneous emphysema) is not equivalent to a negative eFAST.** Large adolescents often require a curvilinear (2-5 MHz) transducer, while the majority of children require the phased array transducer (2-8 MHz) transducer.

The following are the 3 major areas of fluid dependence. The most sensitive location for fluid accumulation in adults is the hepato-renal recess BUT in children, it is the PELVIC CAVITY.

1) **Hepato-renal recess (Morison's pouch)**
2) **Spleno-renal recess**
3) **Recto-uterine recess (pouch of Douglas)** or **Recto-vesicular recess**

KEY ANATOMICAL POINTS

The pelvis has direct interaction with the hepato-renal recess via the right paracolic gutter. There is a left paracolic gutter however fluid accumulation is limited by the phrenico-colic ligament.

The epiploic foramen is another area of free fluid transition between the spleno-renal and hepato-renal recesses.

Free intraperitoneal fluid will always collect in the lowest recesses dependent on positioning. Note, however, that the pelvic cavity will often overflow and cause significant intraperitoneal fluid overflow into the hepato-renal recess via the right paracolic gutter.

The left side of the abdomen accumulates in the subphrenic space before overflowing into the spleno-renal recess and then into the hepato-renal recess.

Tips before starting

- The pointer always points to the head in eFAST. The patient should be supine.
- Always ensure to visualize the entire right kidney and the entire left kidney on quadrant scans.
- A 5-10 degree Trendelenburg will improve sensitivity of fluid detection.
- Inspiration will allow for the liver, spleen, and heart to come into view if having difficulty.
- The RUQ should always be completed prior to log-rolling a trauma patient to maximize sensitivity of the RUQ.

Hepato-renal (RUQ)

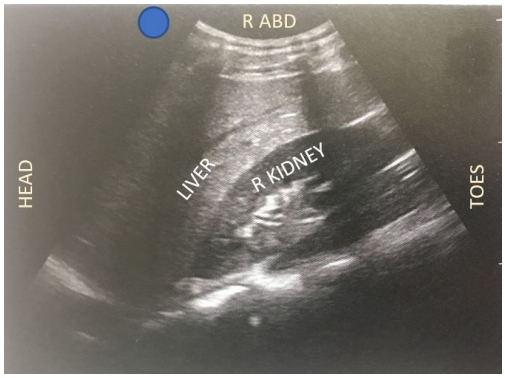

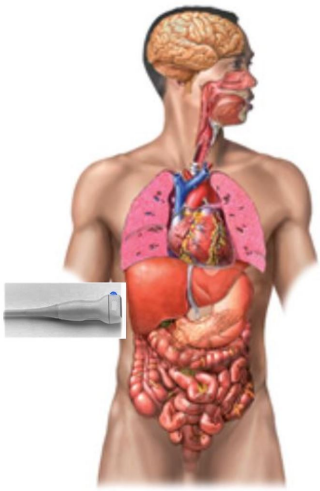

- 85% of positive eFAST have fluid in the Morison's pouch. As little as 250 mL can be detected.
- **Orient transducer longitudinally (coronally) and cephalad (towards head)** on the right flank.
- Begin at the costal margin approximately at the midaxillary line.
- Always visualize the hepatorenal junction.
- Sweep anterior to posterior and superior to inferior through the <u>entire</u> kidney and its perirenal junctions.
    - Tip: When sweeping, tilt the probe. Do not lift probe off of the skin.
- The diaphragm can be visualized if placed slightly cephalad. In the event of any difficulties observing Morison's pouch, mobilize the transducer longitudinally along the rib cage as well as anteriorly and posteriorly.
- Normal images show a bright white line between the liver and right kidney. Abnormal images with fluid would appear *anechoic*.
- Note that the diaphragm will appear as a hyperechoic line.

Spleno-renal (LUQ)

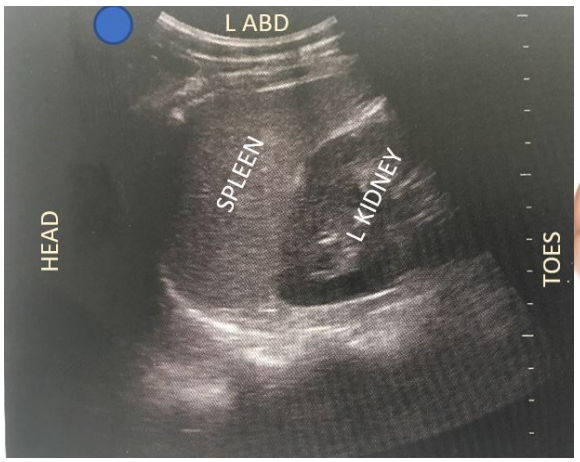

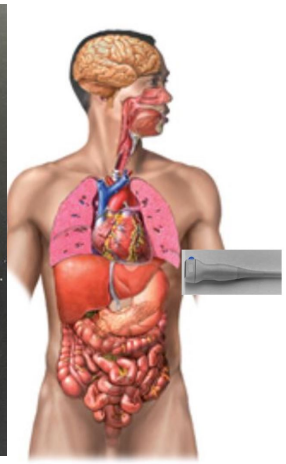

- **Orient transducer longitudinally (coronally) and cephalad (towards head)** on the left flank.
- Note that the left kidney is more superior-posterior than the right kidney. Begin imaging posterior to the midaxillary line. The probe as a result will almost touch the bed. Ensure that your wrist is in a neural position. A 10 degree posterior oblique orientation is often ideal for the long-axis left kidney.
- Sweep anterior to posterior as well as superior to inferior to complete the splenorenal scan. Do not be deterred as there are typically more rib shadowing that obscure the splenorenal junction.
- Fluid accumulation can occur between the spleen and kidney however it is limited by the phrenicocolic ligament. Fluid often accumulates infrarenal, suprarenal, or beneath the diaphragm.
- Perinephric fat can mimic free fluid. Always compare both kidneys in this case.

Suprapubic (Pelvic)

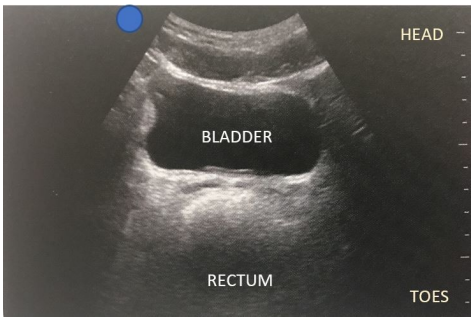

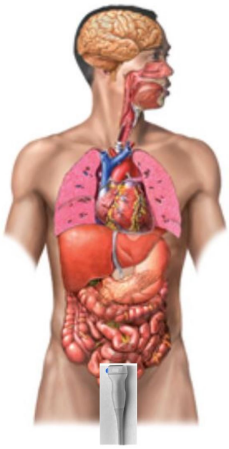

- recto-vesicular pouch (males) OR rectouterine pouch/pouch of Douglas (females)
- **most dependent area of the abdominal cavity in children**
- Understand that there is physiologic fluid in menstruating women, male prostate, and fluid within the bowel loops.
- Place the transducer transversely (horizontally) immediately superior to the pubic symphysis. Orient the transducer to the patient's right side. Ensure that the screen is also oriented to the superior left side.
- Sweep inferiorly until the entire bladder can be visualized. Adjust to the the proper depth encapsulates the entire bladder on the screen.
- Rotate 90 degrees with the transducer oriented to the patient's head and obtain a comparable sagittal view. Refer to Section 6 for calculation of bladder volume.
- Free fluid accumulates posterior or adjacent to the bladder. Adjustment to gain is often necessary.

Subxiphoid (Cardiac)

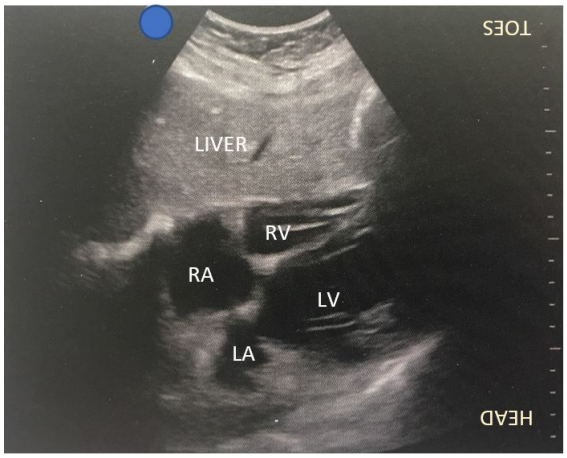

- Evaluates cardiac activity and detect pericardial effusion
- Place the transducer subxiphoid and orient to the patient's right side. Ensure to angle slightly up towards the patients left shoulder. Hold the transducer unlike other views with palm facing downwards with thumb and fingertips on patient's abdomen.
- Slight steady pressure may help to eliminate bowel gas obstructing view.
- The left lobe of the liver is an acoustic window that enhances cardiac imaging.
- Ensure to increase the depth in this view in order to encapsulate the posterior pericardium as well.
- Fluid accumulation is expected to first accumulate posteriorly in a supine patient. Moderate pericardial effusion will extend towards the apex, and a large pericardial effusion would circumscribe the heart. Each of these are medical emergencies and may require emergency pericardiocentesis.
- Cardiac tamponade is a clinical diagnosis, however, Beck's triad of low blood pressure, distended neck veins, and distant muffled heart sounds is not always apparent. Cardiac ultrasound shows circumferential pericardial effusion, paradoxical diastolic collapse of the right ventricle, and the "swinging heart."
- Note that the pericardial fat pad is found anterior to the right ventricle and is often confused for effusion due to its hypoechoic presentation.

<u>Pulmonary</u> (PLEASE REFER TO SECTION 2 for further explanation)

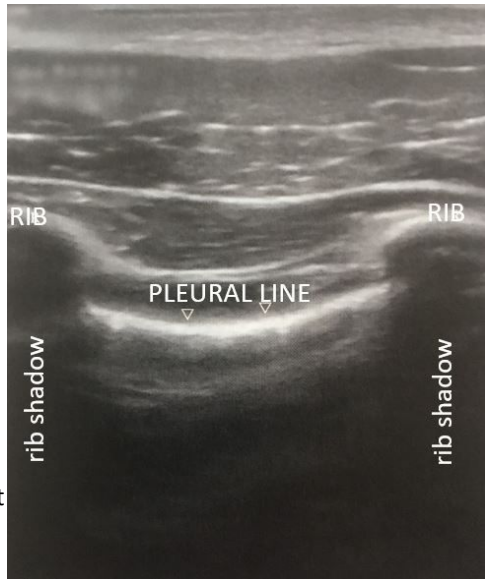

The transducer should always be held steady for 3-4 respiratory cycles to ensure inspiratory-expiratory anatomy.

Place the transducer longitudinally (coronally) oriented to the patient's head. Move the transducer slowly inferiorly unil the hyperechoic diaphragm is identified.

> A mirror image artifact of the liver or spleen is indicative of no fluid in the pleural cavity. Therefore, the absence of the mirror image artifact is indicative of fluid collection. In trauma, this is considered hemothorax until proven otherwise.

Then, place the transducer longitudinally on the midclavicular line at the 3rd to 5th intercostal space. Scan inferiorly with the transducer between two ribs forming rib shadows.

Abnormal findings (please refer to Section 2 on Pulmonary POC Ultrasound)

- Absent lung sliding
- Absent comet tail artifact
- No seashore sign on M-mode
- Stratosphere sign on M-mode
- Lung point on M-mode

- Repeat these scans along the anterior axillary line beginning at the 4th intercostal space.
- Repeat these scans along the posterior axillary line beginning at the 6th intercostal space.

Section 4. Soft Tissue and Musculoskeletal Point of Care Ultrasound

Musculoskeletal Ultrasound: Muscles & Tendons https://vimeo.com/41682960	**MSK** https://vimeo.com/50144679	**Soft Tissues** http://5minsono.com/soft-tissue-5-min-vid-2/

Soft Tissues



Hyperechoic line shows the bone at the bottom of the picture, striae of the muscle is observable above the bone, fascial plane separates the muscle from the Subcutaneous tissue

Linear Transducers typically have a maximum depth of 6 centimeters.

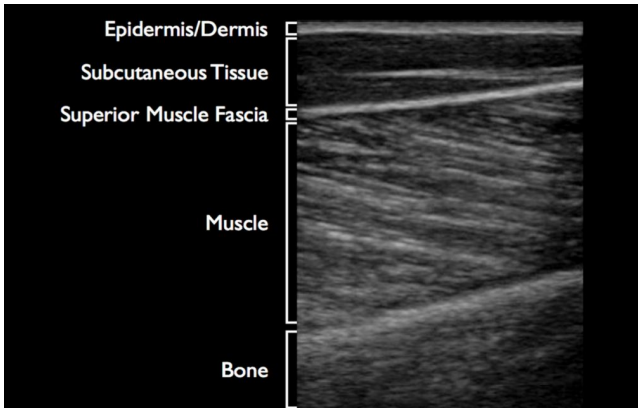

Cellulitis

Pockets of hyperechoic (light) soft tissue surrounded by anechoic (dark) fluid which indicates inflammation in the area, known as **cobblestoning**.

Edema can also look similar but can be differentiated by physical exam (if it looks red its most likely cellulitis)

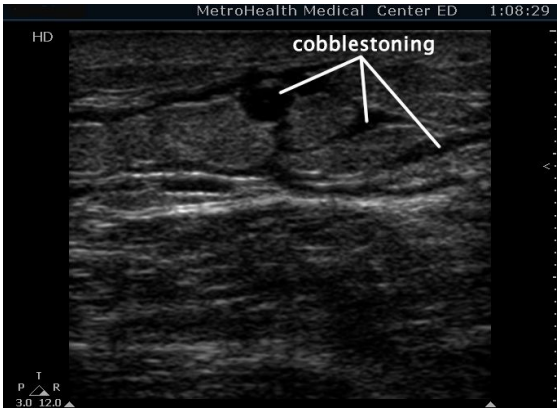

Abscess

Discrete pocket of anechoic fluid; sometimes particles can be seen moving within an abscess.

Must be differentiated from a lymph node or vessel.

Lymph Node

Lymph node can present like an abscess, but will show blood flow with doppler, unlike an abscess. A blood vessel will show pulsatile flow with doppler.

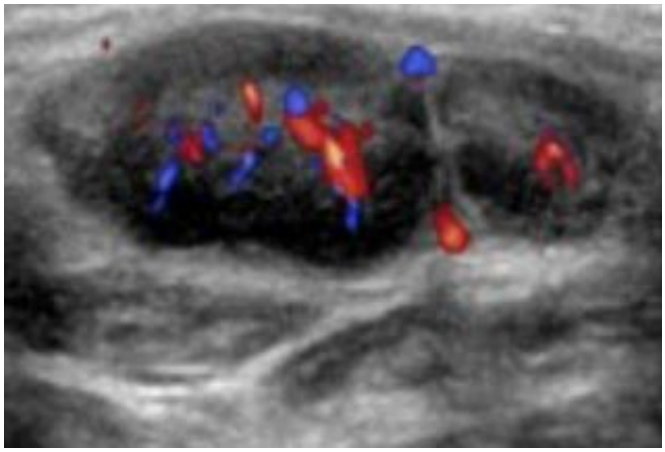

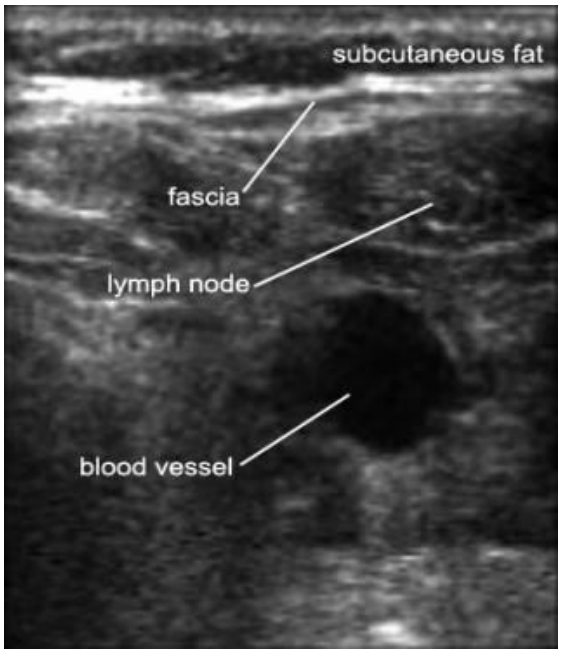

Joint Effusion

Enlargement of the suprapatellar bursa by more than 2 mm is indicative of a knee effusion. To optimize image acquisition one can move the transducer to medial or lateral aspect of the patella along the same longitudinal plane.

Providing pressure over the suspected effusion often reveals compressibility.

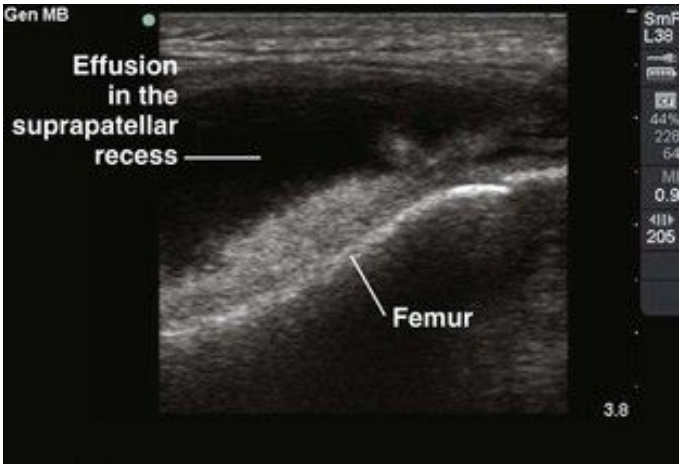

Foreign Body

Best to visualize in two orthogonal planes and to remove in the plane of their longest axis to minimize tissue disruption.

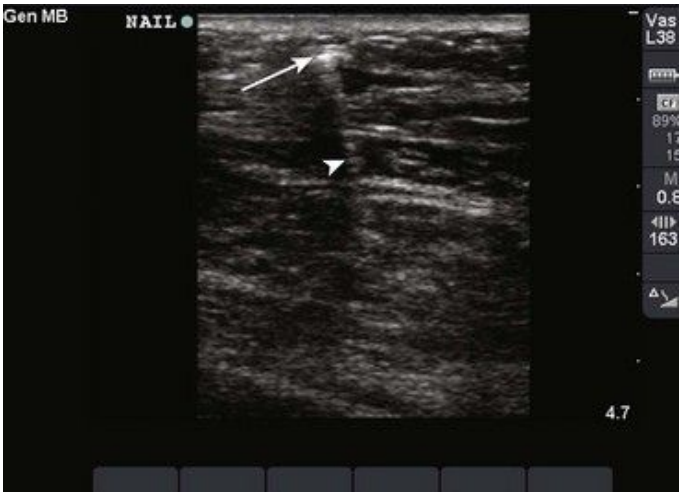

Fracture

Longitudinal AND transverse images should always be obtained.
Look for irregularity of the hyperechoic bony cortex, step-off deformities, overlapping of fracture fragments, and/or presence of avulsion fragments for long bone fractures

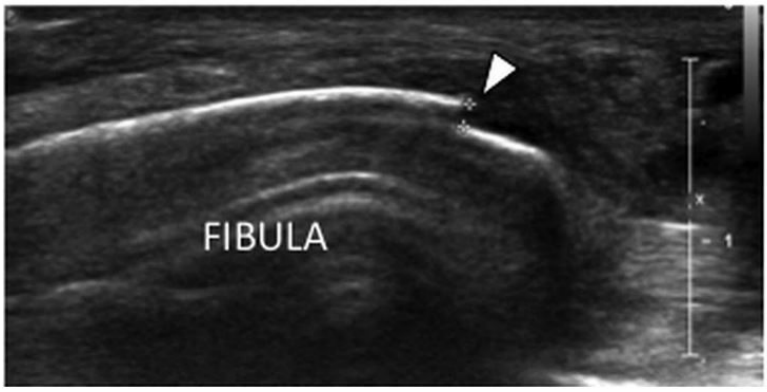

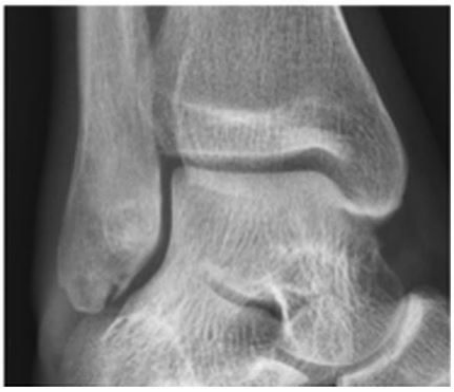

Section 5. Transabdominal Point of Care Ultrasound for Adolescent Females

Transabdominal Pelvic Ultrasound (28:25) https://vimeo.com/41808262

In the female adolescent presenting with acute, non-traumatic abdominal pain, the ultrasound exam can be a great utility. Before using transabdominal U/S it is important to take a careful medical history and perform a urine pregnancy test. This technique can also detect a fetus of 6-7 weeks gestation.

BEFORE YOU BEGIN



A low frequency (2-5 MHz) curvilinear or phased-array transducer is best used which will provide the necessary penetration to evaluate abdominal structures.

Ensure a full bladder as it is used as a sonographic window.

TRANSVERSE abdominal view has the indicator oriented to the RIGHT SIDE OF THE PATIENT.
SAGITTAL abdominal view has the indicator oriented towards the patients HEAD.

It is important to see the structure in two planes to obtain a 3-D understanding of the structure in space.

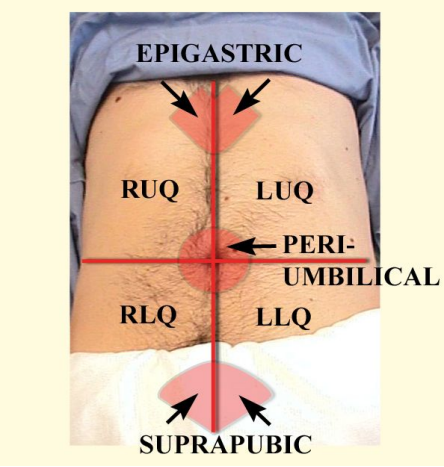

Scanning Approach:

- Place the transducer in the **suprapubic** region of the abdomen.
- A full bladder can aid in the visualization of the uterus and ovaries by providing an acoustic window.
- The patient should be in a supine position with a slight REVERSE Trendelenburg position tol allow better visualization of free fluid in the pelvis.

Transabdominal *TRANSVERSE* View

Bladder appears as an anechoic rectangular or trapezoidal structure

Uterus / Ovaries are located posterior (deep) to the bladder

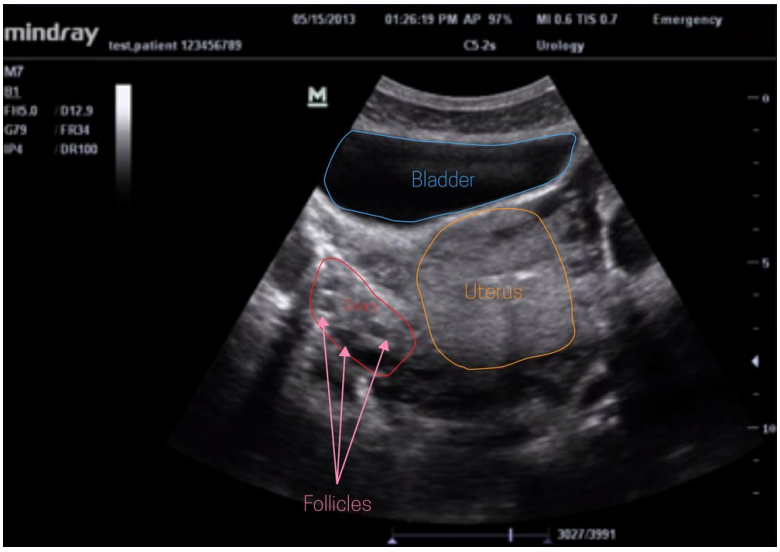

Transabdominal *SAGITTAL* View

Bladder appears as a wedge

Uterus appears Left of the bladder

Pouch of Douglas should always be evaluated as it is often a site for free fluid collection.

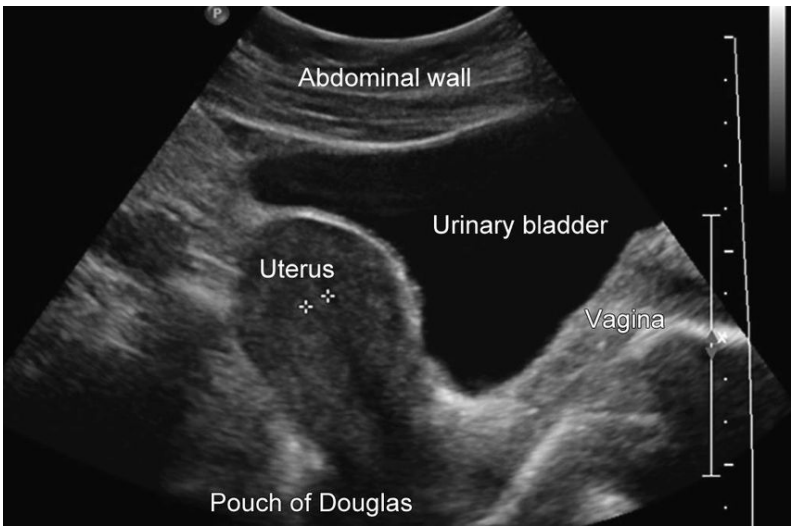

Section 6. Miscellaneous

Inferior Vena Cava

Inferior Vena Cava Ultrasound (30:23) https://vimeo.com/59095991	**Ultrasound Guided Peripheral IV Placement (10:56)** https://vimeo.com/41543020

The IVC can be used as a tool to assess volume status with ultrasound. Changes in diameters can be seen with inadequate hydration.

The IVC AP diameter will be at its maximum during expiration and minimum during inspiration.

The IVC is formed by the union of the common iliac veins around the level of the umbilicus. It runs anterolateral to the spine and right of the abdominal aorta.

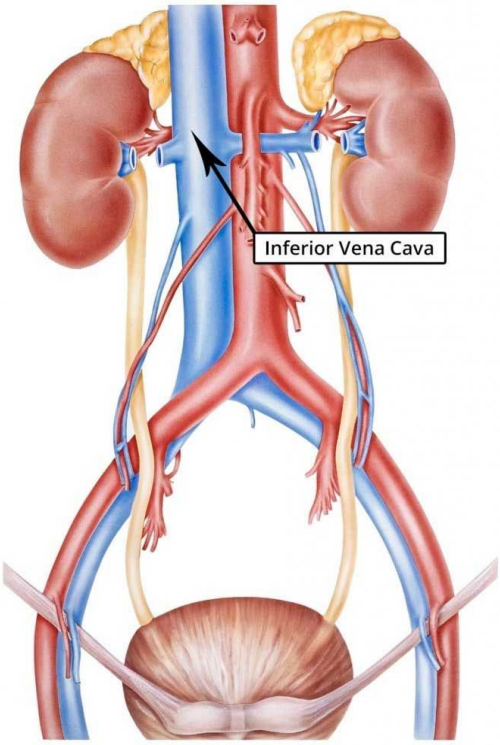

All measurements of the IVC are the AP diameter. A caval index > 50% is strongly associated with a low central venous pressure, although recent studies are controversial in those less than 5 years of age. Regardless, it is a good and easy adjunct test for fluid status in any setting. The walls of the IVC should not “kiss” if adequately hydrated.

$$\textbf{Caval Index} = \frac{\max(IVC) - \min(IVC)}{\max(IVC)} \times 100$$

Patient Positioning should be in the supine position. Gentle pressure may be applied to displace bowel gas which can obstruct the view of the IVC.

Subxiphoid Transverse View
Place the transducer just caudal to the xiphoid process with the indicator oriented towards the patient's right side. The transducer is oriented perpendicular to the patient's body to achieve an accurate cross-section of the IVC.

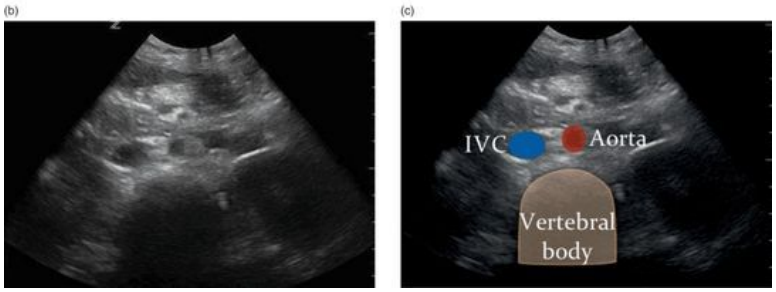

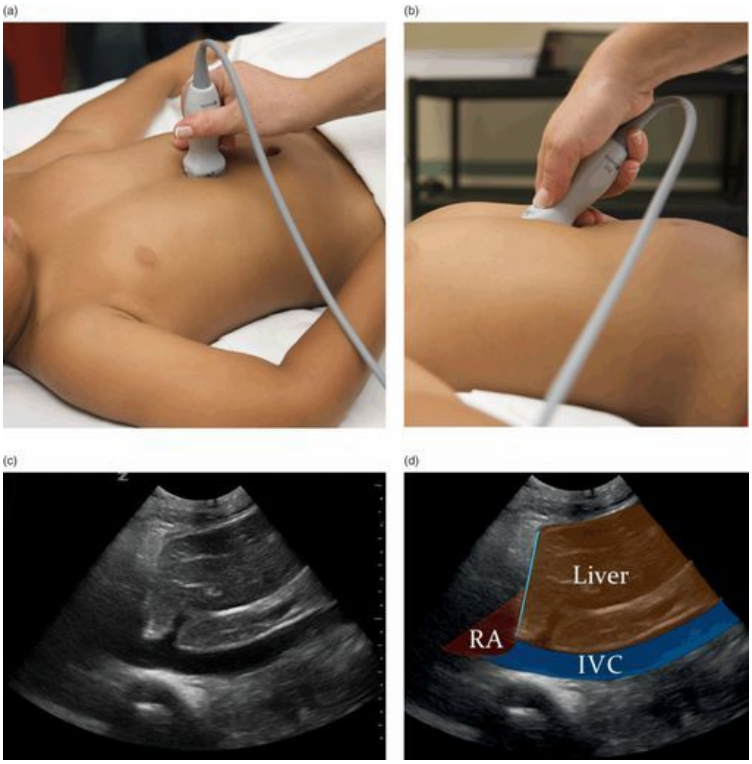

Subxiphoid Longitudinal View
Same as above, but rotate the transducer 90 degrees clockwise, with the indicator pointed towards the patient's head. The transducer should be angled slightly towards the patient's right.

Bladder Volume

Use the phased array transducer.
Locate the pubic symphysis by manual palpation.
Place the transducer immediately superior to the pubic symphysis.
Slowly angle inferiorly into the pelvis.
Begin with the Transverse View (indicator towards patient's right) before the Sagittal View (indicator toward patient's head). Always scan both planes.
Freeze images to obtain measurements.
A full bladder will appear spherical, and a small bladder volume will appear trapezoidal.

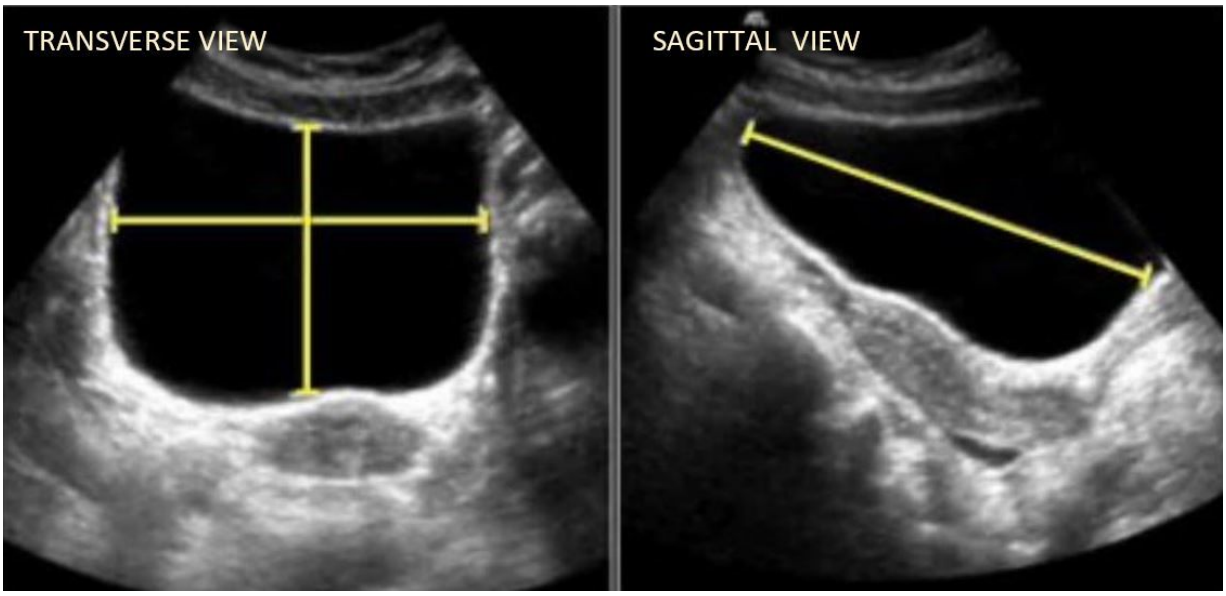

Bladder Volume for age (cm^3 or mL) = [age in years + 2] x 30 cm^3

Manual Bladder Volume Calculation (cm^3 or mL) = [width (cm) x length (cm) x depth (cm)] x 0.75

There are several correction factors, but 0.75 is very commonly used and easily remembered.
Any volume more than 3 mL is usually adequate for urine collection via catheterization in 98% of children.